

# TRM<sup>®</sup>

# METRIDENT - EQ

## Case Study: Management of Incisor Gingivitis in a Senior Mare Using Metrident-EQ

### PATIENT PROFILE

Garbosa, a 21-year 7 months old Spanish mare, was examined on 31 July 2025 for progressive incisor dental issues.

### CLINICAL FINDINGS

On presentation, the mare exhibited:

- Heavy dental calculus accumulation
- Gingival recession and discomfort
- A fistula over the apical area of incisor 402

Radiographic assessment confirmed an apical infection of tooth 402, with no significant abnormalities detected in the remaining incisors.



# TRM<sup>®</sup>

# METRIDENT - EQ

To Support Normal Equine Periodontal Health

## TREATMENT

The therapeutic plan included:

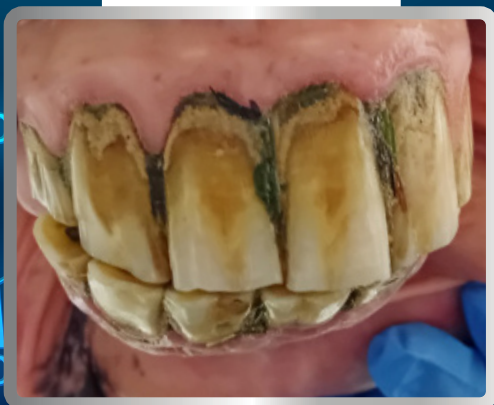- ✓ Extraction of incisor 402
- ✓ Comprehensive dental scaling of the remaining teeth
- ✓ Administration of Metrident-EQ at 50 g daily for two months
- ✓ Regular tooth cleaning performed by the owner

## OUTCOME

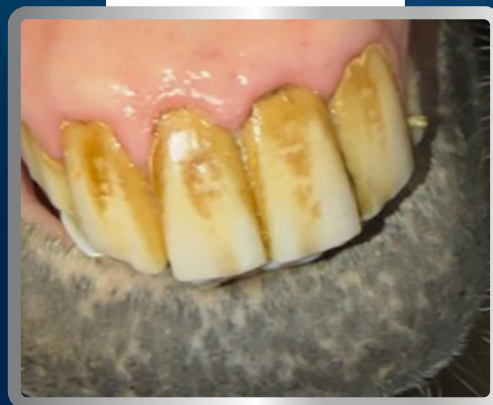
Following treatment and supportive care, the mare demonstrated marked gingival improvement and Garbosa is doing clinically well.



BEFORE



AFTER



## CONCLUSION

This case illustrates the effective use of Metrident-EQ as part of a multimodal treatment approach to manage incisor gingivitis in an aged equine patient.